

## CASE REPORTS

# Peripheral Subcutaneous Neurostimulation in the Management of Neuropathic Pain: Five Case Reports

Claudio Reverberi, MD, FIPP\* • Cesare Bonezzi, MD<sup>†</sup> • Laura Demartini, MD<sup>†</sup>*\*Pain Therapy Center, Oglio-Po Hospital, Vicomosciano, Cremona, Italy; <sup>†</sup>Pain Therapy Center, Maugeri Foundation, Pavia, Italy*

## ABSTRACT

**Introduction.** Spinal cord stimulation (SCS) is an effective treatment option for neuropathic pain. However, because of the obvious procedural issues, SCS is unable to reach certain areas, such as the face, thorax, coccyx, the cervico-dorsal and lumbar areas, and the sacral, abdominal, and inguinal regions. On the other hand, these areas are easily reached by subcutaneous field stimulation. **Methodology.** We report the analgesic results, using a visual analog scale (VAS), of five patients with neuropathic pain treated with subcutaneous field stimulation to the area. We also discuss the probable mechanism of action, and highlight the technical issues inherent to this approach. **Results.** Significant pain reduction and reduction in analgesic medication were reported in all patients during the study period, with VAS scores consistently lowered by more than 50% from baseline levels. As a result of pain reduction, the patients' quality of life improved. There were no adverse events reported except for early electrode array displacement in two of our patients. **Conclusion.** When SCS is not appropriate for certain neuropathic pain syndromes, subcutaneous field stimulation may be used with some degree of efficacy.

**KEY WORDS:** *Neuropathic pain, peripheral stimulation, subcutaneous stimulation.*

## Introduction

Neuropathic pain is the result of present or past damage to the central nervous system or peripheral nervous system. Neuropathic pain persists even after removal of the cause, and frequently becomes chronic because of peripheral or central sensitization (wind-up phenomenon). These phenomena generate hyperalgesia, allodynia, and expansion of the receptive fields as a result of the activation of wide dynamic range neurons in spinal laminae I and II (1).

Spinal cord stimulation (SCS) is effective in many patients with neuropathic pain of the upper and lower extremities and in the lumbo-sacral region, as it appears to transmit retrograde stimulation to the afferent fibers of posterior spinal cords, not synapsed with the first spinal interneuron

(2). In cases of pain afferent from the trunk (paravertebral and presacral regions), the thorax, and the abdomen, SCS may be less successful because paresthesia is difficult to generate when using this procedure. In these cases, peripheral dorsal nerve root stimulation may sometimes be effective, the only drawback being that stimulation of the dorsal root may trigger painful tetanic muscle contractions in the region being stimulated.

Subcutaneous field stimulation easily generates paresthesia in the areas specified above and, if the treated areas are relatively limited in size, can result in effective pain control (3–6).

The efficacy of field stimulation could be explained by the fact that the induced electrical field peripherally

reaches the central nervous system via physiological anterograde conduction, through activation of the intact intradermal receptor and neuron systems (our hypothesis). Using this relatively simple technique, the targeted painful area can be reached directly, without the recruitment of the motor fibers that results in tetanic spasm of the muscle.

We present here the results of our case study of five patients with neuropathic pain of over 6 months' duration, treated with subcutaneous field stimulation for pain control from January to September 2006.

## Case Reports

Our five cases summarized below include a patient with paravertebral back pain, with lumbo-sacral unilateral back pain who was unsuccessfully trialed with SCS, a patient with persistent subacute neck pain and muscle spasm, a patient with an iatrogenic lesion of the greater occipital nerve, and a patient with essential trigeminal neuralgia and pain in the infraorbital and supraorbital regions of the face. All patients were informed of the clinical experimental nature of the proposed treatment and of the absence of effective therapeutic alternatives, and all agreed to the procedure. All patients signed a specific informed consent for the treatment.

Each patient was instructed on how to clean and disinfect the skin at home in preparation for the procedure and all received preoperative prophylactic antibiotic treatment with ceftriaxone 2 mg (intravenously) directly in the operating room, 10 minutes before device implantation.

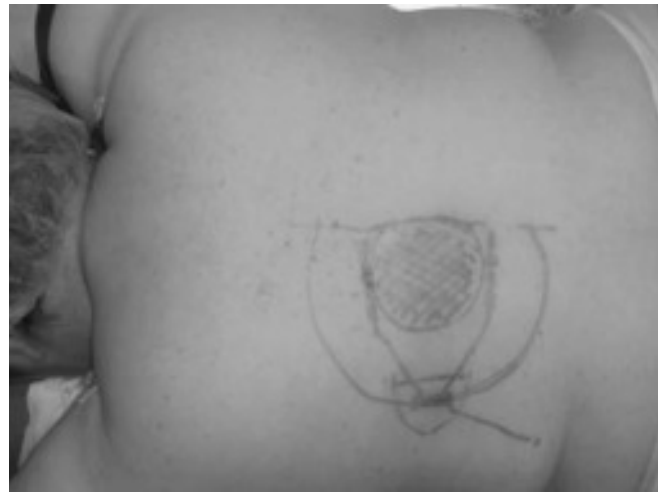The follow-up was done by nurses from our surgeon division, who were not involved in this study. The nurses conducted direct interviews with every patient.

### Case Report 1

A 36-year-old woman presented to our center in March 2006, complaining of severe pain in her upper left back at the level of the T5–T8 dermatomes (visual analog scale [VAS] = 10) that had been persistent for approximately 1 year (Fig. 1).

The pain increased continuously and did not respond to any and all drug treatments tried, which include 400 mg/day of an oral nonsteroidal anti-inflammatory drugs (NSAID), 1500 mg/day of oral gabapentin, opioids (60 mg/day oxycodone), sedatives (1 mg/night clonazepam), and local injection treatments, including corticosteroids infiltrations and pulsed radiofrequency of the appropriate medial branches and posterior dorsal root ganglion. Side-effects, such as gastric pain, drowsiness, dizziness, and space and time disorientation, were intolerable and added to the patient's severe discomfort.

On examination, allodynia and hyperalgesia were present within the painful area and extended proximally. Anesthesia dolorosa was not present.



**FIGURE 1.** Hyperalgesic dorsal area (case no. 1).

This painful areas could not be easily reached by SCS or dorsal nerve root stimulation; we therefore decided to implant two quadripolar electrode arrays (Pisces-Quad, Medtronic Inc., Minneapolis, MN, USA) in the subcutaneous tissue at the upper and lower edge of the painful area (Fig. 2), which was anchored to the muscle fascia and connected to an external stimulator through a temporary extension during the study period. We used the following programmed parameters:

- amplitude: 2 V (upper) and 2 V (lower)
- frequency: 20 Hz
- pulse width: 300 msec

Electrode polarities were set as follows:

- upper electrode 0 (–) 1 (null) 2 (null) 3 (+);
- lower electrode 0 (+) 1 (null) 2 (null) 3 (–).

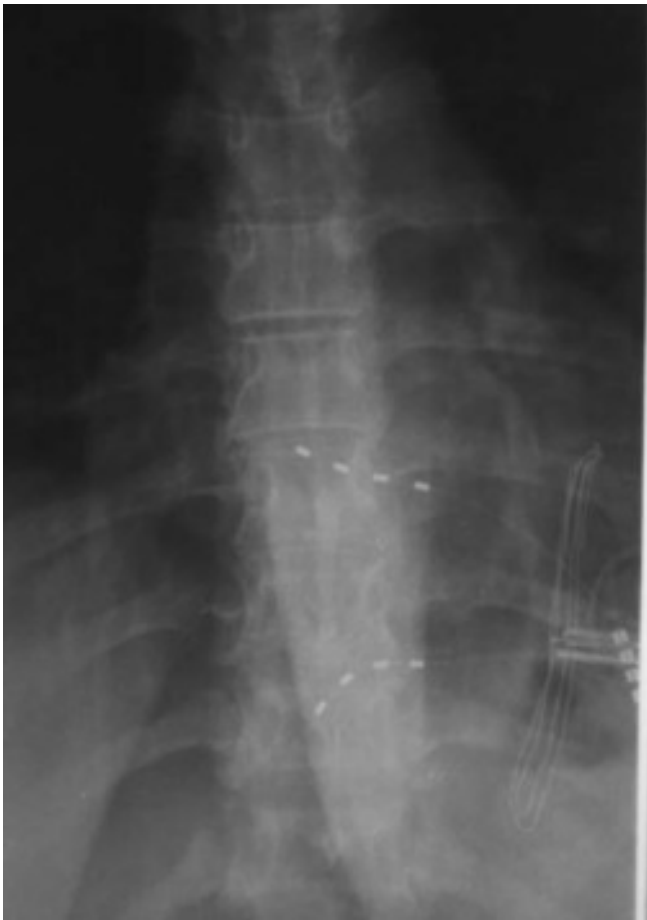Our objective was to induce paresthesia to the edges of the pain area in order to block allodynic sensations without direct stimulation of the allodynic area itself.

During the trial, the patient experienced immediate reduction of nocturnal pain (VAS decreased from 10 to 4), and was able to decrease her use of pain medications, halving the opioid dosage and gradually discontinuing gabapentin.

This reduction in pain medication usage alleviated most of her side-effects and the patient appeared more alert and better oriented in time and space at the subsequent follow-up visit.

As her pain reduction remained constant and after completion of the trial (45 days), a permanent neuropulses generator (Versytrel, Medtronic Inc.) was implanted to the para-umbilical area of the abdominal wall.

Device settings remained unchanged after implantation, except for the frequency, which was reduced to 10 Hz to



**FIGURE 2.** Frontal X-ray view (case no. 1).

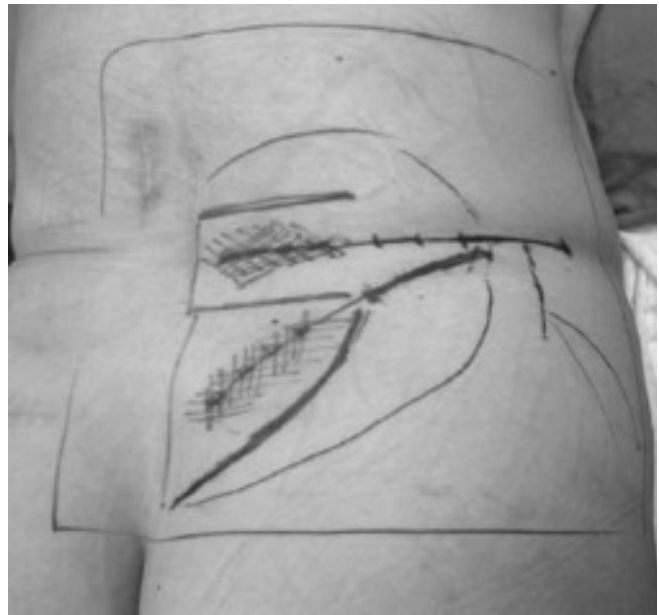impact upon the body's initial tolerance to the treatment. Her frequency was programmed to cyclic mode (5 sec on and 15 sec off) to reduce the probability of further tolerance to stimulation. No adverse events occurred, and the patient resumed her normal everyday activities. The most evident result of field stimulation was the patient's complete recovery from mechanical allodynia in the cutaneous painful area.

At subsequent follow-up visits (3, 6, and 12 months), the antalgic effect, in terms of VAS, remained constant, and no adverse events were reported in connection with the implant.

### Case Report 2

A 65-year-old woman presented to our center in May 2005 complaining of unilateral low back, lumbo-sacral pain radiating to the lower limbs. This pain was the consequence of severe spinal stenosis caused by lumbo-sacral spondyloarthrosis.

The patient's condition was further complicated by neurogenic claudication with paresthesia and pain in the lower limbs. The patient's pain was intractable to trials of several medication, including 400 mg/day of oral tramadol,



**FIGURE 3.** Hyperalgic lumbo-sacral area (case no. 2).

35 µg/h of transdermal buprenorphine, and 1800 mg/day of gabapentin.

This patient underwent implantation of a quadripolar percutaneous electrode array (Pisces-Quad, Medtronic Inc.) in the epidural space at vertebral levels T8–T9 for pain control and mainly for neurogenic claudication.

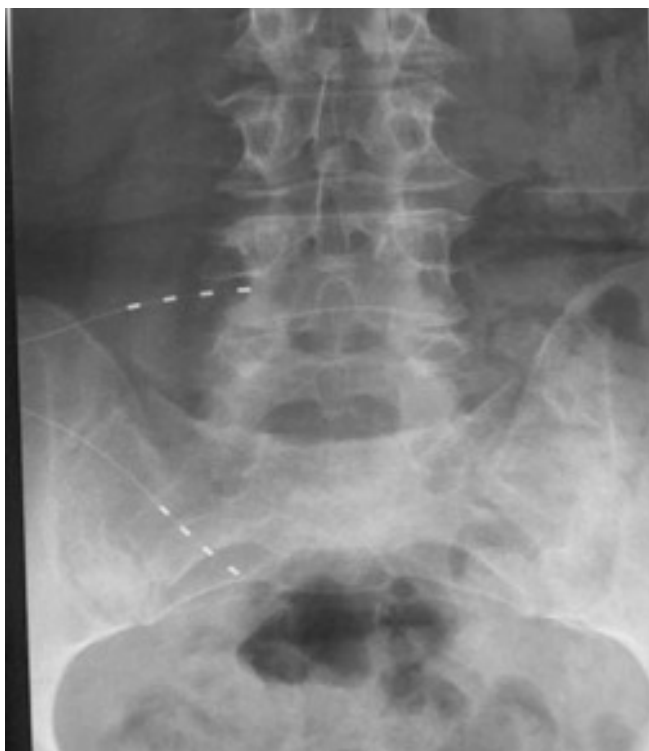During the study period, the patient reported satisfactory pain reduction, no painful paresthesia in her extremity, and improved walking ability; however, she continued to experience pain at the L5 and S1–S2 levels in the right paravertebral area, which was not reached by SCS (Fig. 3). In this relatively small, hyperalgic area, the pinch and roll maneuver caused a sharp painful response, known as "Maigne's cellulalgic syndrome" (7).

In March 2006, after two zygapophysial injections and intra-articular blocks were performed unsuccessfully in the right sacroiliac joint, it was decided to implant two subcutaneous electrode arrays (Pisces-Quad Model, Medtronic Inc.) at the paravertebral levels L5 and S1–S2, respectively (see Fig. 4).

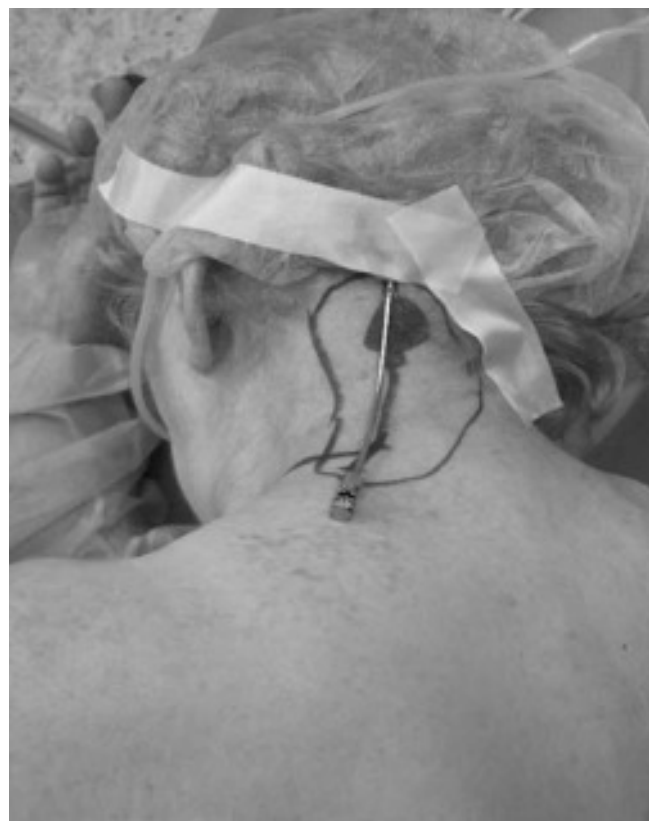During the trial period, the electrode arrays were connected to temporary extensions and to an external stimulator; for both electrode arrays, the stimulation parameter settings were as follows:

- amplitude: 2.5 V
- frequency: 20 Hz
- pulse width: 300 msec

Electrode polarity for both electrode arrays was 0 (+) 1 (+) 2 (+) 3 (-).



**FIGURE 4.** Frontal X-ray view (case no. 2).



**FIGURE 5.** Hyperalgetic cervical zone (case no. 3).

The patient felt mild paresthesia in the pain area, even at low signal amplitude, and after 1 week reported significant pain reduction (VAS score down from 10 to 2).

Her use of pain medications was substantially reduced; gabapentin was gradually discontinued and the dose of tramadol was decreased to 100 mg/day.

At the end of the 6-week study period, it was decided to implant a permanent device (Versytrel) in the gluteal region.

The patient subsequently further reduced the tramadol dosage to 50 mg/day and stimulation amplitude was brought down to 1.5 V in a cyclic mode (5 sec on and 15 sec off).

At the subsequent follow-up visits, up to 12 months after implantation, no changes were made to the settings as the patient continued to report sustained pain relief.

### Case Report 3

In January 2006, a 71-year-old woman presented to our center reporting severe pain in the left cervical region, extending from the occiput to the base of the neck and into expanding to the trapezius muscle and the ipsilateral shoulder. This pain originated from C1–C3 vertebrae, and this area exhibited a complete block caused by a painful antalgic contracture (Fig. 5). Examination revealed a marked muscle contracture, and light pressure provoked a hyperalgetic response.

The patient did not benefit from drug treatments, which included analgesics, tramadol, muscle relaxants, and local infiltrations with corticosteroids, while rehabilitation treatments (cervical traction and manipulation) had not only been ineffective but actually aggravated the pain.

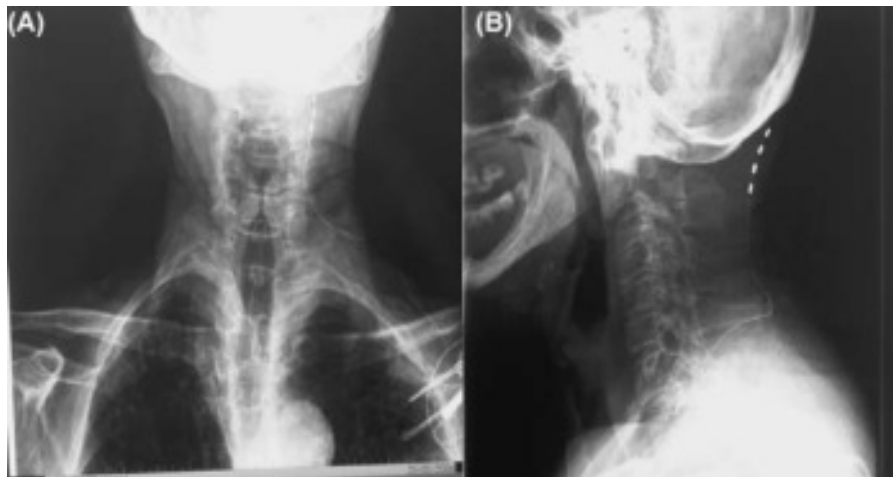
Diagnostic examinations (X-ray, magnetic resonance imaging and computed tomography scan) showed no significant neuromuscular or skeletal malformation, except for severe arthrosis and left zygapophysis deformation at C1–C2 and C2–C3 levels.

A pulsed radiofrequency procedure was performed on the medial branches of the cervical posterior roots at these levels, on the assumption that the patient was suffering from cervical facet syndrome. After 1 month, the patient reported that she had only experienced 2 weeks of partial pain reduction, followed by a relapse of her pain.

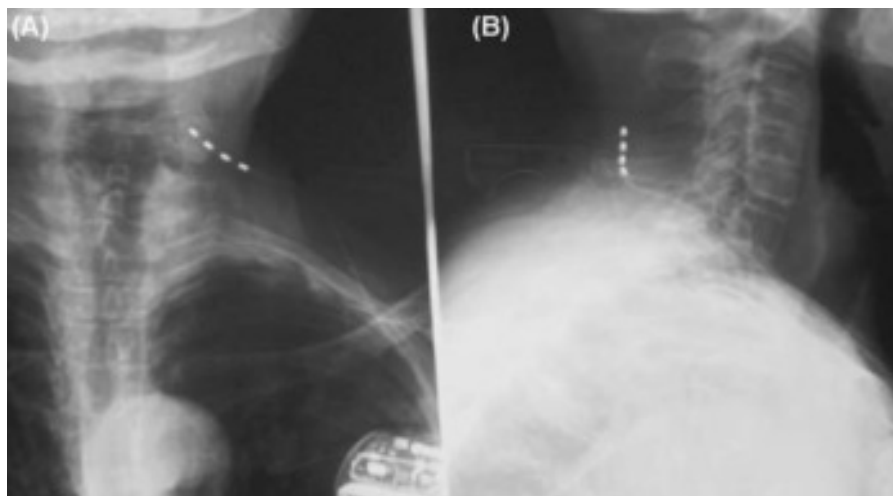
In April 2006, it was decided to implant a quadripolar electrode array (Quatrode, ANS Inc., Plano, TX, USA) within the subcutaneous tissue of the hyperalgetic area (Fig. 6A,B).

The parameters were set as follows:

- amplitude: 1.2 mA
- frequency: 20 Hz
- pulse width: 210 msec



**FIGURE 6.** Frontal and lat. X-ray views (case no. 3).



**FIGURE 7.** Frontal and lat. X-ray views of dislocation electrode (case no. 3).

The polarity selected for the electrodes was 0 (+) 1 (+) 2 (+) 3 (-).

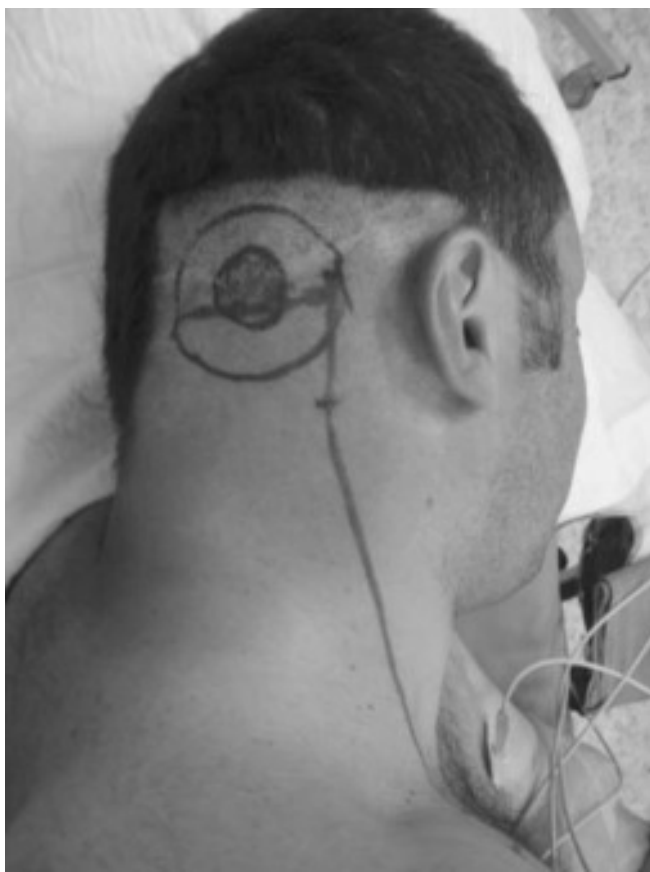During the trial period, the patient reported marked and immediate pain relief (VAS score down from 9 to 2), partial recovery of cervical mobility, and reduction in the use of analgesics and muscle relaxants. A permanent neuromodulator (Genesis model, ANS Inc.) was implanted in a subcutaneous pocket in the left subclavicular region. Two months after implantation, the patient returned to our observation reporting a relapse of the pain and paresthesia sensations in the left trapezius muscle and shoulder. Cervical X-rays revealed a downward displacement of the electrode array (Fig. 7A,B). The device was repositioned and secured to the fascia through a double-cone silicone fixation system, creating a loop distal to the fixation area.

Once the electrode array was repositioned, the stimulation again induced paresthesia in the pain area, resulting in immediate pain relief, which confirmed that the analgesic effect is correlated to the proper positioning of the array concordant to the pain area, rather than to any external factors or nonspecific, placebo effects.

To date, the patient still reports a significant level of pain relief, has not used analgesic drugs, and reports no adverse events as a consequence of her implant.

#### Case Report 4

In September 2006, a 36-year-old man presented to our center complaining of severe right occipital neuralgia that had been persisting for 5 years and had started as a result of an iatrogenic greater occipital nerve lesion from a hair



**FIGURE 8.** Iatrogenic lesion of greater occipital nerve with hyperalgetic area.

transplant procedure (Fig. 8). A large number of ectopic sites (neuromas) had developed, causing severe and frequent drop attacks.

Medication management (600 mg/day pregabalin) and radiofrequency ablation of the neuromas were ineffective and aggravated the patient's pain. It was decided to treat the patient with pulsed radiofrequency of the posterior dorsal ganglion of the right C2–C3 roots and after treatment the patient experienced satisfactory pain relief for at least 3 months. When the pain and drop attacks reappeared, we repeated the pulsed radiofrequency treatment with partial success that lasted for 1 month.

In January 2007, it was decided to implant an ultrathin quadripolar electrode array (Axxess model, ANS Inc.) in the subcutaneous, occipital tissue, proximal to the nerve lesion and parallel to the scar, and connected to an external stimulator. This electrode array was selected in consideration of the very limited thickness of the subdermal tissue at this level and to minimize the risk of decubitus ulcers and patient discomfort. Parameter settings were as follows:

- amplitude: 1.1 mA
- frequency: 20 Hz

- pulse width: 210 msec
- programmed polarity: 0 (+) 1 (+) 2 (+) 3 (–).

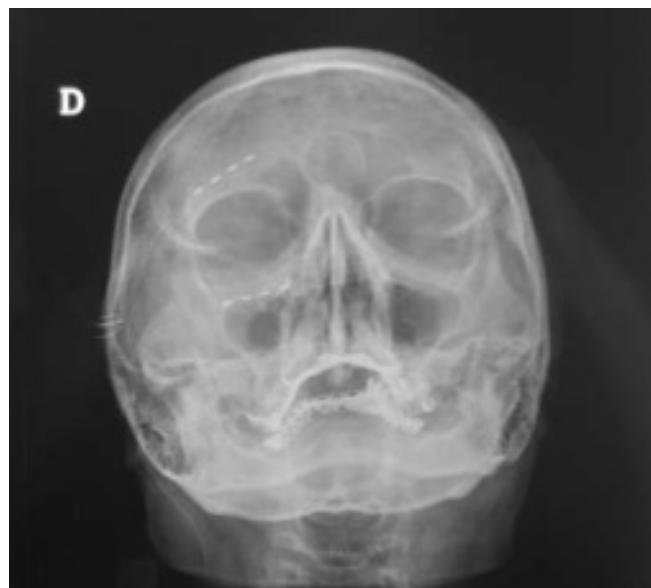
The patient reported mild paresthesia within the painful area, immediate pain relief (VAS score down from 8 to 0), discontinuance of his pain medication, and disappearance of his drop attacks. After 6 weeks of sustained complete pain relief, it was decided to implant a permanent stimulator programmed to operate in cyclic mode (Genesis, ANS Inc.).

At follow-up visits, the patient reported a consistent satisfactory level of analgesia (VAS score = 3) and disappearance of drop attacks, with marked improvement in his quality of life.

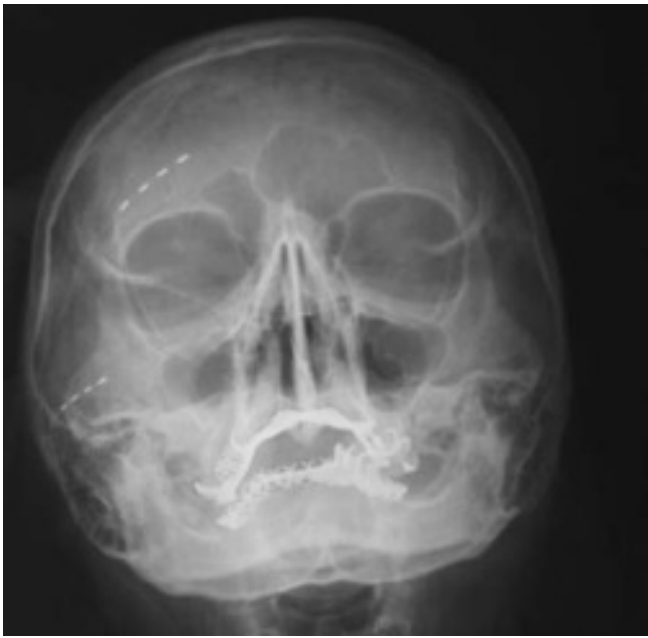### Case Report 5

In July 2006, a 61-year-old woman presented to our center with severe pain in her face and mouth. She had been diagnosed with “essential trigeminal neuralgia” in the area of first and second branch of fifth cranial nerve (trigeminal nerve), with her pain originating from the infraorbital level and extending to the right eye, frontal and supraorbital region, mouth, tongue, and pharynx.

In the previous 2 years, the patient had undergone two gasserian, ganglion-level radiofrequency thermorhizotomy procedures, which resulted in only transient and partial pain reduction, and she was currently receiving 1200 mg/day of oral oxcarbamazepine. As the patient refused any further surgical intervention (vascular decompression, gamma knife, etc.), it was decided to implant two ultrathin quadripolar, subcutaneous electrode array (Axxess, ANS Inc.) in the facial region, at the emergence of the infraorbital and supraorbital nerves (Fig. 9).



**FIGURE 9.** Frontal X-ray view (case no. 5).



**FIGURE 10.** Frontal X-ray dislocation infraorbital lead (case no. 5).

During the trial period, the arrays were connected to an external generator via temporary extensions. Her settings were programmed as follows:

Supraorbital level:

- amplitude 1.2 mA
- frequency 20 Hz
- pulse width 200 msec
- programmed polarity 0 (+) 1 (+) 2 (+) 3 (-)

Infraorbital level:

- amplitude 1.5 mA
- frequency 20 Hz
- pulse width 200 msec
- programmed polarity: 0 (+) 1 (+) 2 (+) 3 (-)

The entire pain area was covered by mild paresthesia, and the patient immediately reported a reduction of her trigeminal facial pain (VAS from 10 to 1). After 6 weeks of stimulation, the patient reduced her medication dosage to 600 mg/day, and it was therefore decided to implant a permanent pulse generator (Genesis, ANS Inc.) in a pocket created in the right subclavicular region. After 5 months of complete pain relief, the symptoms suddenly reappeared.

An X-ray confirmed lateral displacement of the infraorbital catheter (Fig. 10), which was immediately replaced and repositioned in its original placement, and the device was reprogrammed to operate in cyclic mode. Since replacement, the patient has experienced satisfactory facial pain relief, although she occasionally still suffers from buccal

pain and dysphagia. However, to date she is subjectively satisfied with the trigeminal neuromodulation treatment and has not increased analgesic medication dosage.

### Technical of Implant

It is our practice that before implantation, the size and contours of the pain areas should be accurately identified, and the potentially hyperalgetic or allodynic areas should be outlined using dermatographic pencils of different colors. The marked pain areas are then photographed, and the photograph is shown to the patient for confirmation that pain distribution and location have been correctly identified.

The procedure can be performed under general anesthesia or deep sedation, avoiding local anesthesia in the area to be stimulated. A quadripolar electrode can cover a pain area of approximately 100 cm<sup>2</sup>; two quadripolar electrodes or one octopolar electrode may be used depending on the anatomy and location of the area, avoiding the allodynic areas where stimulation may be painful. We believe that paravertebral electrode arrays should be preferably implanted perpendicular to the spine (although parallel implantation is also possible), sloping downwards at the cervical and lumbo-sacral level, in the direction of the posterior branches of the spinal nerve.

Stimulation should occur in the plane between the dermis and subcutaneous tissue (subdermal stimulation), rather than deep within the fascial plane, to avoid inducing tetanic muscle contractions when the stimulation is turned on, which may be painful to the patient. This subdermal surface exhibits high receptor and nerve density (Fig. 11), and when stimulated with an electric field it is possible that the impulse is transmitted to the central nervous system, through the afferent pathways in the physiological anterograde direction (our hypothesis).

It is our practice that through a small incision, a Tuohy needle is inserted in the proximity of the pain area until it reaches the fascial plane, and then advanced upwards until it reaches the subdermal area where the electrode is implanted.

Electrode array fixation must be performed with extreme care, as displacements and ruptures of the array are, in our experience, frequent, especially in the facial and cervical regions (case reports 3 and 5) and in the areas subject to friction or movement as in extremities.

As no specific fixation systems are currently available for subcutaneous field stimulation, this procedure may be performed by creating a subcutaneous pocket next to the needle insertion site, fixing the electrode array to the fascia using a silicone double cone device, and creating a large catheter loop distally to the fixation point (Fig. 12). Another suggested method for fixation is based on the use of the Interstim system (Medtronic Inc.), where the electrode is coated with a silicone tab system that anchors it securely

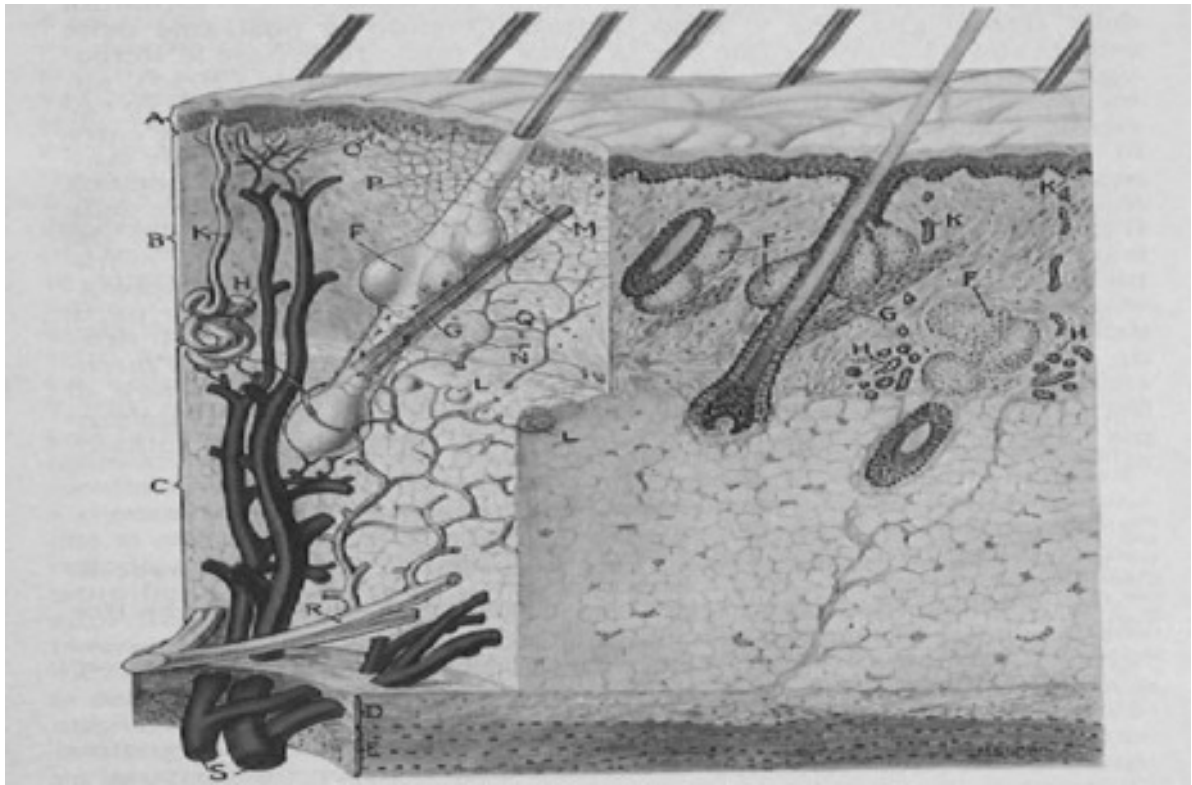


FIGURE 11. Section of subcutaneous and dermal tissue (Gray's Anatomy, London).

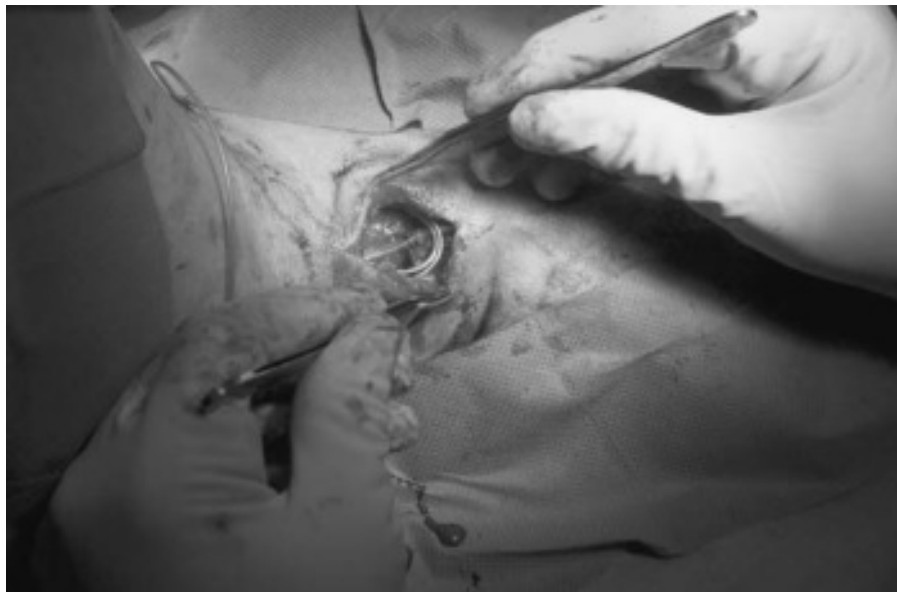


FIGURE 12. Anchorage system of subcutaneous lead.



to the tissues, the only drawback being difficult removal in case of explantation.

During the trial period, the catheter is connected to an external stimulator through a temporary extension (as with SCS) and during this trial time special care should be taken to prevent infections, especially in the case of electrodes implanted in extremities. Currently available neuropulse generators or rechargeable batteries are not small enough to be implanted next to the treated area; therefore, they must be placed in the traditional sites (subclavicular, abdominal, or gluteal), which are sometimes distant from the electrode implantation sites.

## Discussion

Peripheral nerve electrostimulation is a widely used technique for the treatment of neuropathic pain, and numerous reviews have been published on the use of percutaneous and surgical implantation of electrodes on and around peripheral nerves that have suffered traumatic lesions or entrapment (8,9).

Conversely, peripheral electrical field stimulation is less well used, although it may prove useful in cases of cervicogenic headache and nerve entrapment syndromes (5,6). This technique can be used in the treatment of neuropathic pain of different origins and located in areas that are difficult or impossible to reach using SCS (in particular the skull, face, thorax, paravertebral and presacral areas, inguinal and perineal regions, hands and feet). The treatment is most indicated in cases where the pain area is limited, the pain is severe, and it cannot be treated with analgesic medications or other therapies.

Transcutaneous electrical nerve stimulation (TENS) may be used as a preliminary diagnostic test, but not as a prognostic test, as the skin's electrical impedance differs between individual patients, and electrode position and adhesion in the pain area is variable. For these reasons, peripheral subcutaneous electrical field stimulation is far more effective than TENS for many pathological conditions (10).

Subcutaneous stimulation can be used to treat cervicogenic headaches or headaches of unknown origin located in the parietal, temporal, or frontal regions (5,11,12).

It may also be effective with atypical facial neuralgias and with trigeminal pain, especially when the ophthalmic branch is affected (13). According to some studies, the technique also allows patients to reduce their pain reliever dosage (10,13,14), as was also observed in all of our five cases. A specific indication, as demonstrated by the case of patient no. 3, is paravertebral pain in the cervical, dorsal, and lumbar region, as well as in the thoracic, abdominal wall, and inguinal regions, often affecting limited areas described as "Maigne's cellalgic zones" (7).

These symptoms are reported in patients with both peripheral and central sensitization phenomena, who may eventually develop localized causalgia syndrome (15).

Possible mechanisms of action of subcutaneous field stimulation include:

- central neuromodulation, with the stimuli transmitted through intact A-beta and A-delta fibers to the spinal cord (physiological anterograde activation);
- local effect of the electric field on the dermal nerves and receptors (C-system); and
- electrical stimulation may have a direct local anti-inflammatory and membrane-depolarizing effect, reducing the sensitivity of circulating catecholamines.

Studies within the literature confirm an increased level of anti-inflammatory cytokines in areas treated with radiofrequency for pain relief purposes (16), as well as a direct anti-inflammatory effect on stimulated tissues (17).

As the case reports suggest, correct electrode array positioning is the one essential requirement that must be met in order to obtain satisfactory therapeutic effects, while considerable doubt remains as to appropriate stimulation parameter settings.

Anodes seem to have higher analgesic effects than cathodes; a frequency of 20 Hz (or lower) may be optimal to obtain long-term presynaptic inhibition of pain impulse transmission (Long-Term Depression) to the central nervous system (18,19). Pulse width may affect the expansion of the electric field and recruitment of small-diameter fibers, just as in SCS (20), and cyclic-mode operation may prevent or delay peripheral receptor adjustment with possible loss of pain-relieving effects (tolerance).

In our experience, the most significant complication was displacement of the electrode array, particularly those placed within the cervical and facial regions. To reduce the occurrence of this complication, the electrodes must be securely fixed to the fascial plane. Although less frequent, infections, decubitus ulcers, and electrode array breaks are also possible; in our experience, we observed three cases of infections in two extremity implants and one cervical implant, and two cases of ultrathin electrode breaks in areas subject to friction and traction. Decubitus ulcers may occur if the electrode array tip is placed too superficially, compressing the corneal layer, or if the skin is too fragile, as in the case of vasculopathic or diabetic patients or patients chronically treated with corticosteroids.

Lastly, special care should be exercised in treating patient with certain medical comorbidities that include rheumatoid arthritis, fibromyalgia, and scleroderma, and that present a high risk of formation of aberrant scar tissue at and in the implant site. This scar formation may result in electrode entrapment and potential worsening of the patient pain; additionally, difficulties may arise when removing the electrode, which may break and remain partially in the implant site (this case occurred in our experience). In these cases, the use of ultrathin electrode array (Axxess quadripolar lead, ANS Inc.) may be indicated;

these devices, however, have a high breakage rate and are difficult to fix.

## Conclusion

We conclude that subcutaneous field stimulation is effective for neuropathic pain syndromes and as supplementary therapy to traditional SCS and peripheral nerve electrostimulation. The development of dedicated devices (electrodes and generators) to this form of therapy should contribute to this methodology's safety and applicability, reducing the occurrence of implantation problems, which are still the main limit to a wider use of this approach.

## Conflict of Interest

The authors reported no conflict of interest.

## References

1. Bonezzi C, Demartini L. *Pain Chronic Therapy Based on Pathogenetic Mechanism*. Amsterdam, The Netherlands: Elsevier, 2006.
2. Buonocore M, Bonezzi C, Barolat G. Neurophysiological evidence of antidromic activation of large myelinated fibres in lower limbs during spinal cord stimulation. *Spine* 2008;33:E90–E93.
3. Monti E. Peripheral nerve stimulation: a percutaneous minimally invasive approach. *Neuromodulation* 2004;7:193–196.
4. Michael H, Daniel MD. Perineuronal stimulation in the treatment of occipital neuralgia: a case study. *Neuromodulation* 2001;4:47–51.
5. Maria Dolores R-R, José MA, José Q, Maria CL, Pilar A, Javier A. Peripheral neurostimulation in the management of cervicogenic headache: four case reports. *Neuromodulation* 2005;8:241–248.
6. Lawrence WS Jr, Grant TR, Nancy EC, Bennet ED. Peripheral subcutaneous electrostimulation for control of intractable post-operative inguinal pain: a case report. *Neuromodulation* 2001;4:99–104.
7. Maigne R. *Diagnostic et Traitement des Douleurs Communes D'Origine Rachidienne*. Paris, France: Expansion Scientifique Française, 1989.
8. Hassebusch SJ, Stanton-Hicks M, Schoppa D, Walsh JG, Covington EC. Long-term results of peripheral nerve stimulation for reflex sympathetic dystrophy. *J Neurosurg* 1996;84:415–423.
9. William PC, Cooney, MD. *Hand Clin* 1997;13(3).
10. Vladimir K, Murray EB. *Transcutaneous Electrical Nerve Stimulation, MPH* (January) 2007;26.
11. Oh MY, Ortega J, Bellotte JB, Whiting DM, Alo KM. Peripheral nerve stimulation for the treatment of occipital neuralgia and transformed migraine using a C1-2-3 subcutaneous paddle style electrode: a technical report. *Neuromodulation* 2004;7(2):103–112.
12. Popeney CA, Aló KM. Peripheral neurostimulation for the treatment of chronic, disabling transformed migraine. *Headache* 2003;43:369–375.
13. Konstantin VS, Chrystian W. Trigeminal branch stimulation for intractable neuropathic pain. Technical Note. *Neuromodulation* 2005;8(1):7–13.
14. Gloria G. Contemporary treatment strategies in idiopathic trigeminal neuralgia. *Patient Care* October 1, 2005.
15. Racz GB, Lewis R, Heavner JE et al. Peripheral nerve stimulation implant for the treatment of causalgia. In: Stanton-Hicks M, Janig W, Boas RA, eds. *Reflex Sympathetic Dystrophy*. Norwell, MA: Kluwer, 1990:135–141.
16. Connor W, O'Neill MD. Percutaneous plasma decompression alters cytokine expression in injured porcine intervertebral discs. *Spine J* 2004;4:88–98.
17. Elrich J, Lamp S. Peripheral nerve stimulation inhibits nociceptive processing: an electrophysiological study in healthy volunteers. *Neuromodulation* 2005;8:225–232.
18. Bear MF. Bidirectional synaptic plasticity: From theory to reality. *Phil Trans R Soc Lond B Biol Sci* 2003;358:649–655.
19. Sandkuhler J, Chen JG, Cheng G, Randic M. Low frequency stimulation of afferent A $\delta$  fibers induces long-term depression at primary afferent synapses with substantia gelatinosa neurons in the rat. *J Neurosci* 1997;17:6483–6491.
20. Thomas Yearwood L, Brad H, Lee D, Kerry B. Dorsal column selectivity in pulse width (PW) programming of spinal cord stimulators (SCS): the "Sacral Shift 0148". INS 8th World Congress, December 9–12, 2007, Acapulco, Mexico.