

ORIGINAL ARTICLE

Year : 2015 | Volume : 63 | Issue : 5 | Page : 707-711

Neuromodulation as a last resort option in the treatment of chronic daily headaches in patients with idiopathic intracranial hypertension

Andrew B Shaw, Mayur Sharma, Ammar Shaikhouni, Evan S Marlin, Daniel S Ikeda, John M McGregor, Milind Deogaonkar

Department of Neurosurgery, Center of Neuromodulation, Wexner Medical Center, The Ohio State University, Columbus, Ohio, USA

Date of Web Publication 6-Oct-2015

Correspondence Address:

Milind Deogaonkar

Department of Neurosurgery, Center of Neuromodulation, Wexner Medical Center, The Ohio State University, 480 Medical Center Drive Columbus, OH 43210

USA

 Login to access the email ID

Source of Support: None, Conflict of Interest: None



DOI: 10.4103/0028-3886.166534

 Get Permissions for commercial use

>> Abstract

Objective: To determine the feasibility and efficacy of occipital nerve stimulation (ONS) in patients with refractory headaches secondary to idiopathic intracranial hypertension (IIH).

Background: IIH is a syndrome characterized by elevated intracranial pressures in the absence of a mass lesion. These patients typically present with chronic and intractable headaches. Cerebrospinal fluid (CSF) diversion fails in relieving the headache in a significant proportion of this population. ONS has been shown to be effective in medically refractory headaches and to our knowledge, has not been attempted as a therapeutic modality in this population.

Methods: Four patients with occipital predominant chronic daily headaches and IIH who failed medical management underwent bilateral ONSs. Octopolar percutaneous electrodes were implanted in the defined area of pain. Visual Analog Scale (VAS) was used as an outcome measure. Patient demographics and surgical complications were also reviewed in this retrospective study. Following the trial period, all patients had >50% pain reduction resulting in permanent implantation.

Results: All 4 patients had an average improvement of their VAS scores by 75%, with 85% spatial coverage and the remainder of the uncovered region being frontal. Sustained benefits were seen up to 3 years of follow-up. One patient had a lead erosion requiring removal followed by delayed re-implantation and another lost treatment efficacy at 2 years resulting in explantation. One patient required CSF diversion due to visual threat during the follow-up period but maintained sustained benefit from her ONS.

Conclusions: Bilateral ONS may be a useful treatment option in the management of selected patients with IIH, after standard surgical interventions have been attempted. Bilateral ONS may provide therapeutic option for management of residual headaches in these complicated patients.

Keywords: Headache; idiopathic intracranial hypertension; neuromodulation; occipital nerve stimulation; pseudotumor cerebri

How to cite this article:

Shaw AB, Sharma M, Shaikhouni A, Marlin ES, Ikeda DS, McGregor JM, Deogaonkar M. Neuromodulation as a last resort option in the treatment of chronic daily headaches in patients with idiopathic intracranial hypertension. *Neurol India* 2015;63:707-11

How to cite this URL:

Shaw AB, Sharma M, Shaikhouni A, Marlin ES, Ikeda DS, McGregor JM, Deogaonkar M. Neuromodulation as a last resort option in the treatment of chronic daily headaches in patients with idiopathic intracranial hypertension. *Neurol India* [serial online] 2015 [cited 2015 Oct 12];63:707-11. Available from: <http://www.neurologyindia.com/text.asp?2015/63/5/707/166534>

» Introduction

Idiopathic intracranial hypertension (IIH) is a well-described syndrome involving elevated intracranial pressures (ICPs) without the presence of a mass lesion. The diagnostic criteria include symptoms of elevated ICP (>25 cm of H_2O) with papilledema, no localizing signs, normal brain imaging, normal cerebrospinal fluid (CSF), and no identifiable cause.^[1]
^[2] IIH can be diagnosed in the absence of papilledema with the previously described criteria and unilateral/bilateral cranial nerve VI palsy, empty sella, flattening of posterior aspect of globe, distension of perioptic subarachnoid space with or without a tortuous optic nerve, or transverse sinus thrombosis on magnetic resonance imaging (MRI).^{[2],[3]} Management of these patients requires a multidisciplinary approach. At our institution, we follow over 200 patients with documented IIH. Often these patients require treatment with medications (diuretics, carbonic anhydrase inhibitors), optic nerve decompressions, and CSF diversion.^[4] Serial lumbar punctures (LPs) can be performed as a temporizing measure to reduce ICP, which may in turn improve the headache symptomatology. Dietary management resulting in weight loss as low as 6% has been shown to reduce papilledema and the vascular phenomena associated with IIH; and, there is often recurrence of papilledema with weight gain.^{[3],[5],[6]} After vision has been protected, these patients often present with chronic daily headaches.^[3] CSF diversion has been shown to improve headache; however, at 36 months following the procedure, 48% of patients will have persistent headache despite a functioning shunt, with 80% undergoing revisions.^{[3],}
^[7] This is likely because CSF diversion improves headache related to the increased ICP but not other types of headache that are frequently observed in this patient population. These include the tension headaches, migraine, low-pressure headaches due to over shunting, and medication-overuse headaches.^{[3],[5],[8]} In our experience, a subset of patients continues to suffer from disabling headaches even after multimodality medical treatment.

Recently, occipital nerve stimulation (ONS) has been shown to effectively improve medically refractory headaches by stimulation of large sensory afferents.^{[9],[10],[11],[12],[13],[14]} The mechanism of action has not been completely elucidated till date but continues to be based on the gate control theory of pain. It has been suggested that the mechanism of action may result from chronic depolarization of sensory afferents, C-fiber inhibition, various neurotransmitters, and even activity at the level of the thalamus.^[13] Therefore, we postulated that the use of this treatment modality may be beneficial in patients with IIH with medically refractory headaches. Here, we describe our experience in using this technique in 4 patients referred to our practice. To our knowledge, this is the first report on the role and efficacy of ONS in the treatment of refractory headaches in patients with IIH.

» Methods

Four patients with IIH, who underwent ONS over a 3-year period, were included in this retrospective series. All 4 patients were Caucasian females with an average body mass index of 36.8 kg/m^2 and ages ranging from 26 to 37 years [Table 1]. Each patient was evaluated with an MRI/magnetic resonance venography to rule out a structural cause prior to their diagnosis of IIH. None had evidence of venous thrombosis or a structural lesion that could explain their increased ICP or evidence of a *Chiari malformation* [More Details](#). Three of 4 patients were managed with CSF diversion including one lumboperitoneal and two ventriculoperitoneal shunt systems. One patient was managed with optimum medical treatment for IIH. However, despite optimum medical management with serial monitoring of her CSF opening pressures, her headache persisted and was attributed as 'chronic refractory' and managed with ONS. All 4 patients underwent multiple LPs with opening pressure measurements to rule out increased ICP as a result of shunt failure as the source of their

headaches. Each patient in this series had a follow-up visit with their neurologist and was diagnosed with a chronic migraine type headache that was predominantly occipital in nature. Variable modes of medical management were attempted including invasive procedures such as nerve blocks and Botox injections. All patients were maintained on several pain medications, but continued to have refractory headaches. Greater occipital nerve (GON) blocks were tried in two of the 4 patients with a short-term benefit. Over time, these blocks became less efficacious. All patients underwent trial implantation of bilateral ONSs (as described below) and had at least 50% reduction in their pain during the trial leading to the decision for implantation of a permanent stimulator. Self-reported verbal analog scale (VAS) scores were obtained during the preoperative evaluation and at last follow-up visits.

Table 1: Summary of demographic data for patients with IIH and headaches

[Click here to view](#)

Surgical procedure

Surgical implantation of electrodes is usually carried out as a staged procedure.^{[15],[16],[17]}x**b**

Trial implantation of electrodes

Occipital nerve stimulator trials were done as an outpatient procedure in a lateral decubitus position. The procedure was performed either using a general anesthetic or monitored anesthesia care. The sub-occipital region was then clipped and prepped. For the trial implantation of electrodes, small skin punctures were made with a Tuohy needle in the sub-occipital region/retromastoid region on one side. An ON-Q[®] (Braun Melsungen AG, Germany) tunneler was molded to match the curvature of the suboccipital region and two sheaths were passed in the subcutaneous plane so as to have one just past the midline and the other near the mastoid contralaterally [Figure 1]. This was done to ensure coverage of both GONs. An octapolar electrode (Octad [Medtronic, Inc., Minneapolis, MN, USA]) was then passed through the sheath. X-rays were obtained to verify appropriate positioning. The sheaths and stylets were removed. The leads were then secured to the skin with 2-0 silk sutures. The patients were discharged following programming for a 7-day trial period with an externalized pulse generator. At the return appointment, efficacy was gauged based on the amount of coverage and percentage of pain reduction using the VAS scoring system.

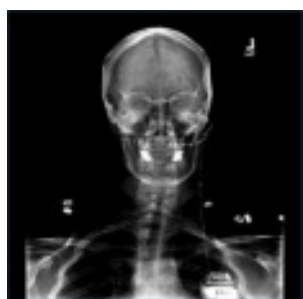

Figure 1: Occipital nerve stimulation system with two octopolar leads. One lead is placed to the contralateral mastoid, and another is implanted just past midline. These leads are then tunneled to the chest to be connected with an IPG

[Click here to view](#)

Permanent implantation of electrodes

Following the successful trial with >50% reduction in pain on VAS scores, permanent implantation was offered as an outpatient procedure. The patient was taken to the operating room for removal of trial leads and for permanent implantation of new leads and an implantable pulse generator (IPG) [Figure 2]. At this stage, the trial leads were removed, and an approximately 4 cm incision was made in the suboccipital/retromastoid region on the side of greater pain. A subcutaneous pocket was then made for anchoring and formation of a strain free loop of wire. The octopolar leads were tunneled to the same anatomic locations as described during the successful trial under fluoroscopic guidance, anchored, and tunneled to the chest. A 4 cm infraclavicular incision with a subcutaneous pocket was made for IPG implantation. Radiographs were obtained following the procedure so as to confirm the continuity and location of the implant as shown in [Figure 3]. Programming was performed in the postoperative period, and the patient was then discharged.

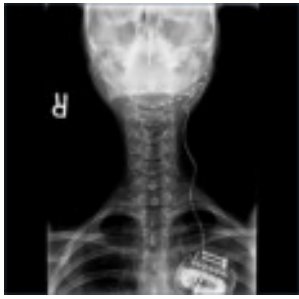

Figure 2: Occipital nerve stimulation system with relief loops at the location of lead anchoring. This helps to reduce the occurrence of lead migration or damage during normal range of motion of the neck

[Click here to view](#)

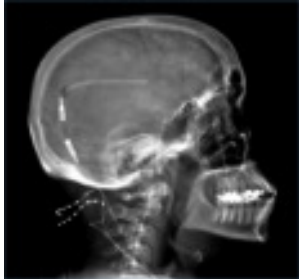

Figure 3: Occipital nerve stimulator in a patient with a right ventriculoperitoneal shunt

[Click here to view](#)

» Results



Occipital nerve stimulation provided at least 50% pain relief in all the 4 patients with refractory chronic daily headaches. The average improvement in VAS scores was 75%. They had an average of 85% spatial coverage of their headache. The remaining uncovered 15% area was frontal in location. Sustained benefit was seen for up to 3 years in 3 patients.

All patients had their vision followed clinically by fundoscopic examination and continued care by their primary ophthalmologist. No visual complications occurred as a result of ONS.

Complications included one lead erosion due to significant weight loss, which was treated by removal of her system followed by 14 days of antibiotics (cephalexin 500 mg every 6 h). Once she completed her course, she underwent re-implantation of her ONS system. Another patient lost treatment efficacy resulting in explantation 2 years after the index procedure. There were no lead infections, lead migrations, lead fractures, or IPG (implantable pulse generator) complications.

One concern during the utilization of neuromodulation therapies in IIH was that it would mask headaches resulting from shunt failure and, therefore, could result in permanent damage to vision due to the delayed diagnosis. However, in this series, treatment of the headaches did not mask the symptoms resulting from elevated ICP. Three patients required treatment with CSF diversion at various points of their care due to the visual threat. One patient was initially managed with a combination of intermittent LPs and medical management, but ultimately required placement of an LP shunt for vision protection. The other two have not required a shunt revision since implantation of the ONS.

» Discussion



Idiopathic intracranial hypertension is a challenging disease that requires collaboration among multiple specialists including neurologists, neurosurgeons, ophthalmologists and pain physicians to manage their chronic pain, vision loss and elevated ICP. Prevention of visual loss should remain the primary goal with the reduction of headache severity and frequency as a secondary objective. This is accomplished with a combination of medical management and surgery. Traditionally, surgery involves a combination of optic nerve sheath fenestration, CSF diversion and subtemporal decompressions. Once the vision has been protected, the secondary goal of headache relief becomes paramount for the patient. Approximately 48% of patients will have some headache improvement with CSF diversion alone, but at 36

months, headaches often return despite a functioning shunt.^{[3],[7]} There is no clear objective measure that reliably suggests headache reduction in an individual patient. Management of headaches should be done in combination with pain physicians and neurologists. All nonmedication-related lifestyle changes for headache hygiene should be tried. The next step often involves medications. A variety of selective serotonin reuptake inhibitors, tricyclic antidepressants and calcium channel blockers should be attempted prior to considering the addition of narcotic analgesics. The complicating factor with narcotic analgesics is medication-overuse headaches, which becomes a self-propagating problem that is difficult to correct.

When medical management becomes inadequate, patients often present for surgical options. Those with CSF diversion for the treatment of elevated ICP seek evaluation of their shunts. This results in frequent physician and emergency department visits with high economic costs and little improvement in their symptomatology.^[18] Once a functioning shunt is determined, patients are left with medical management alone to control their headaches. At this point, narcotics often become part of their management with little overall benefit.

In those with medically refractory headaches, neuromodulation has been shown to significantly reduce cluster and occipital headaches.^{[9],[10],[11],[12],[13],[14],[19]} In this series, all 4 patients had predominant occipital headaches that were not related to elevated ICP and were medically refractory suggesting that they were likely to benefit from peripheral nerve stimulation. In addition, this may further imply the existence of a subset of patients with IIH, who may benefit from ONS. Two of our patients underwent occipital nerve blocks prior to surgical intervention with initial benefit. These 2 patients had a sustained and positive therapeutic response to ONS. The patient whose system was ultimately removed did undergo occipital nerve blocks and Botox injections with a short-term response. She initially had a therapeutic benefit to ONS, but this diminished over time in conjunction with difficulty in charging her IPG that resulted in explantation. We, therefore, suggest that all patients undergo a trial of occipital nerve blocks prior to their being considered for ONS. Based on our experience, patients who respond positively to a nerve block may be better candidates for ONS. However, this does not ensure that patients who do not respond to a nerve block will not respond to ONS.^[20] In our practice, patients deemed to be appropriate candidates for neuromodulation need to undergo neuropsychological testing. The goal is to identify any potential psychological barriers to improvement from neuromodulation. After being considered for surgery, a 7-day trial with external leads is used to identify appropriate coverage and a good response to therapy. In our series, all patients benefitted from trial implantation and underwent permanent implantation.

There are specific nuances to this patient population that need to be considered prior to implantation of a stimulator. First, patients with lumboperitoneal shunts without suboccipital decompression should be counseled about the potential for induced Chiari malformations and the need for myelography to make a diagnosis prior to undergoing ONS implantation. Concern exists for the development of induced Chiari I malformation from over-shunting and the inability to obtain an MRI with the current stimulator technology.^{[15],[21]} MRI is useful for monitoring these potential iatrogenic changes and to ensure that tonsillar herniation is not progressive (that may require shunt ligation or decompressive surgery). Second, in patients with a ventriculoperitoneal shunt, care should be taken with regard to site selection to avoid tunneling near the distal shunt catheter. Tunneling ipsilateral to the shunt could result in damage to the shunt requiring revision/replacement surgery.

We were concerned that ONS in this patient population will interfere with early identification of shunt failure and ultimately place their vision at risk. In this series, ONS did not prevent detection of visual deterioration or the need for shunt revision secondary to elevated ICP. One patient in this series presented with visual complaints and headaches after ONS placement and was found to have increased opening pressure that required placement of a shunt.

Similar to programming parameters described in our previous reports,^{[15],[17]} we have used amplitude, frequency, and pulse width in the range between 0.5 and 2 mAmps, 40 or 50 Hz, and 60–120 μ s, respectively, in this series. A large bipolar configuration with guarded active contacts in obese patients was used in our patients. Lower pulse widths and frequencies were usually better tolerated with occasional cycling.

One of the limitations of this study is its retrospective nature and a small cohort of patients. However, we think that our experience provides an initial evidence supporting the role of ONS in the treatment of refractory chronic headaches in patients with IIH following shunt procedures. Further larger studies will be needed to better understand the efficacy of

this mode of treatment for chronic refractory headaches in patients with IIH.

» Conclusion

Bilateral ONS may be a useful treatment option in the management of patients with IIH following shunt procedures. Once the vision is protected, some patients still suffer from chronic and disabling headaches that are not responsive to CSF diversion procedures. Bilateral ONS may provide a therapeutic option for management of residual headaches in these complicated patients. However, long-term prospective randomized studies in a large cohort of patients are warranted to validate the efficacy of this therapeutic option.












Financial support and sponsorship

Nil.

Conflicts of interest

There are no conflicts of interest.

» References

1. Binder DK, Horton JC, Lawton MT, McDermott MW. Idiopathic intracranial hypertension. *Neurosurgery* 2004;54:538-51. 
2. Friedman DI, Liu GT, Digre KB. Revised diagnostic criteria for the pseudotumor cerebri syndrome in adults and children. *Neurology* 2013;81:1159-65. 
3. Mallery RM, Friedman DI, Liu GT. Headache and the pseudotumor cerebri syndrome. *Curr Pain Headache Rep* 2014;18:446. 
4. Friedman DI, Jacobson DM. Idiopathic intracranial hypertension. *J Neuroophthalmol* 2004;24:138-45. 
5. Newborg B. Pseudotumor cerebri treated by rice reduction diet. *Arch Intern Med* 1974;133:802-7. 
6. Kupersmith MJ, Gamell L, Turbin R, Peck V, Spiegel P, Wall M. Effects of weight loss on the course of idiopathic intracranial hypertension in women. *Neurology* 1998;50:1094-8. 
7. McGirt MJ, Woodworth G, Thomas G, Miller N, Williams M, Rigamonti D. Cerebrospinal fluid shunt placement for pseudotumor cerebri-associated intractable headache: Predictors of treatment response and an analysis of long-term outcomes. *J Neurosurg* 2004;101:627-32. 
8. deSouza RM, Toma A, Watkins L. Medication overuse headache-An under-diagnosed problem in shunted idiopathic intracranial hypertension patients. *Br J Neurosurg* 2015;29:30-34. 
9. Schwedt TJ, Dodick DW, Hentz J, Trentman TL, Zimmerman RS. Occipital nerve stimulation for chronic headache – Long-term safety and efficacy. *Cephalalgia* 2007;27:153-7. 
10. Magis D, Allena M, Bolla M, De Pasqua V, Remacle JM, Schoenen J. Occipital nerve stimulation for drug-resistant chronic cluster headache: A prospective pilot study. *Lancet Neurol* 2007;6:314-21. 
11. Burns B, Watkins L, Goadsby PJ. Treatment of medically intractable cluster headache by occipital nerve stimulation: Long-term follow-up of eight patients. *Lancet* 2007;369:1099-106. 

12. Slavin KV, Colpan ME, Munawar N, Wess C, Nersesyan H. Trigeminal and occipital peripheral nerve stimulation for craniofacial pain: A single-institution experience and review of the literature. *Neurosurg Focus* 2006;21:E5. [↑](#)
13. Slavin KV, Nersesyan H, Wess C. Peripheral neurostimulation for treatment of intractable occipital neuralgia. *Neurosurgery* 2006;58:112-9. [↑](#)
14. Weiner RL, Reed KL. Peripheral neurostimulation for control of intractable occipital neuralgia. *Neuromodulation* 1999;2:217-21. [↑](#)
15. Deogaonkar M, Slavin KV. Peripheral nerve/field stimulation for neuropathic pain. *Neurosurg Clin N Am* 2014;25:1-10. [↑](#)
16. Sharma M, Shaikhouni A, Saleh E, Shaw A, Deogaonkar M. Peripheral nerve field stimulation for otalgia: A novel therapy for refractory deep ear pain. *Interdiscip Neurosurg* 2014;1:101-4. [↑](#)
17. Zibly Z, Sharma M, Shaw A, Deogaonkar M. Peripheral field stimulation for thoracic post herpetic neuropathic pain. *Clin Neurol Neurosurg* 2014;127:101-5. [↑](#)
18. Friesner D, Rosenman R, Lobb BM, Tanne E. Idiopathic intracranial hypertension in the USA: The role of obesity in establishing prevalence and healthcare costs. *Obes Rev* 2011;12:e372-80. [↑](#)
19. Sharma M, Shaw A, Deogaonkar M. Surgical options for complex craniofacial pain. *Neurosurg Clin N Am* 2014;25:763-75. [↑](#)
20. Schwedt TJ, Dodick DW, Trentman TL, Zimmerman RS. Response to occipital nerve block is not useful in predicting efficacy of occipital nerve stimulation. *Cephalalgia* 2007;27:271-4. [↑](#)
21. Johnston I, Jacobson E, Besser M. The acquired Chiari malformation and syringomyelia following spinal CSF drainage: A study of incidence and management. *Acta Neurochir (Wien)* 1998;140:417-27. [↑](#)

Figures

[Figure 1], [Figure 2], [Figure 3]

Tables

[Table 1]